

Zhonghua Sun, Associate Professor, Series Editor

Beta-blocker administration protocol for prospectively ECG-triggered coronary CT angiography

Akmal Sabarudin, Zhonghua Sun

Akmal Sabarudin, Diagnostic Imaging and Radiotherapy Program, School of Diagnostic and Applied Health Sciences, Faculty of Health Sciences, University Kebangsaan Malaysia, Kuala Lumpur 50300, Malaysia

Zhonghua Sun, Discipline of Medical Imaging, Department of Imaging and Applied Physics, Curtin University, Perth 6845, Western Australia, Australia

Author contributions: Sabarudin A prepared and reconstructed the manuscript; Sun Z edited the manuscript.

Correspondence to: Zhonghua Sun, Associate Professor, Discipline of Medical Imaging, Department of Imaging and Applied Physics, Curtin University, GPO Box, U1987, Perth 6845, Western Australia, Australia. z.sun@curtin.edu.au

Telephone: +61-8-92667509 Fax: +61-8-92662377

Received: July 3, 2013 Revised: September 13, 2013

Accepted: October 16, 2013

Published online: December 26, 2013

Core tip: This article provides the protocol of beta-blocker as guidance for prospective ECG-triggered coronary computed tomography angiography (CCTA). With the use of beta-blocker, patients' heart rate can be regulated and controlled to suit the protocol of prospective ECG-triggering CCTA. We believe that this article can give an insight on the management of beta-blocker administration in the coronary computed tomography protocol.

Sabarudin A, Sun Z. Beta-blocker administration protocol for prospectively ECG-triggered coronary CT angiography. *World J Cardiol* 2013; 5(12): 453-458 Available from: URL: <http://www.wjgnet.com/1949-8462/full/v5/i12/453.htm> DOI: <http://dx.doi.org/10.4330/wjc.v5.i12.453>

Abstract

The aim of this article is to discuss the protocol of beta-blockers that is commonly used for prospectively ECG-triggered coronary computed tomography angiography (CCTA). It is essential to ensure a low and regular heart rate in patients undergoing prospectively ECG-triggered CCTA for optimal visualization of coronary arteries. Although early generations of computed tomography-scanners are not applicable to be tailored according to patients' heart rate, a low and regular heart rate is possible to be achieved by the administration of medications according to the beta-blocker protocol. Beta-blocker can be safely administered to reduce patients' heart rate for CCTA examination if patients are screened for certain contraindications.

© 2013 Baishideng Publishing Group Co., Limited. All rights reserved.

Key words: Beta-blockers; Coronary computed tomography angiography; Heart rate; Prospective ECG-triggering

INTRODUCTION

Prospectively ECG-triggered coronary computed tomography angiography (CCTA) is increasingly used in the diagnosis of coronary artery disease (CAD) due to its very low radiation dose with acceptable image quality^[1-3]. This technique not only provides comparable diagnostic accuracy to that of conventional approach, retrospectively ECG-gated CCTA, but also shows superior advantage in reducing radiation dose (up to 83%), which is significantly lower than that from retrospectively ECG-gated protocol^[1-4]. However, in order to ensure that image quality is acceptable for clinical diagnosis, prospectively ECG-triggered CCTA is restricted to patients with low (heart rates less than 65 bpm) and regular (HR variability < ± 5 bpm) during the scan^[1,2,5].

With the advancements of computed tomography (CT) technology, the latest generation of multislice CT scanners enables customization of the scanning protocol to tailor individual patient's condition such as using multiple heart-beat scanning modes or application of additional padding windows^[5,6]. Thus, the prospectively ECG-triggered CCTA

Table 1 Beta-blocking agents

B-blockers Generic name	Selectivity	Partial agonist activity	Lipid solubility	Onset		Hemodynamic effect		Plasma half-life	Elimination's route
				Oral	IV	Oral	IV		
Acebutolol hydrochloride	β ₁	Yes	Low	1-2 h	No	> 24 h	No	3-4 h	Hepatic, renal
Atenolol	β ₁	No	Low	1 h	1-2 min	24 h	12 h	6-9 h	Renal
Betaxolol hydrochloride	β ₁	No	Low	24 h	No	> 24 h	No	12-22 h	Hepatic, renal
Bisoprolol	β ₁	No	Low	1-4 h	No	24 h	No	7-15 h	Hepatic, renal
Esmolol	β ₁	No	Low	No	1-4 min	No	5-10 min	4-9 min	Erythrocyte, renal
Metoprolol tartrate	β ₁	No	Moderate	1 h	5-10 min	5-8 h		3-7 h	Hepatic
Metoprolol succinate	β ₁	No	Moderate	2-3 h	No	24 h	No	3-7 h	Hepatic
Nadolol	None	No	Low	1-2 h	No	24 h	No	20-24 h	Renal
Pindolol	None	Yes	Moderate	1-2 h	No	24 h	No	3-4 h	Hepatic, renal
Propranolol hydrochloride	None	No	High	30 min	< 1 min	6-12 h	4-6 h	3.5-6 h	Hepatic

could be extended to more patients with variable heart rates. However, these protocols suffer from radiation dose which limits the widespread use of the prospectively ECG-triggering technique in cardiac imaging. Therefore, the use of beta-blockers is an option which is widely used in CCTA studies to reduce the heart rate to less than 65-70 bpm and to make the cardiac rhythm more regular^[7].

All of the beta-blockers used in clinical practice are competitive pharmacologic antagonists. Drugs in beta-blocker group can be classified into subgroups on the basis of β₁ selectivity, partial agonist activity, local anesthetic action and lipid solubility (Table 1)^[7,8]. Most of the organ-level effects of beta-blockers are predictable blockade of the beta-receptor-mediated effects of sympathetic discharge. The clinical applications of beta-blockade are broad ranging from treating glaucoma to cardiovascular disease^[8].

The applications of beta-blockers in cardiovascular disease treatment are of paramount importance, especially in the situations such as hypertension, angina and arrhythmias^[8]. However, adverse cardiovascular effects such as bradycardia, atrioventricular blockade and heart failure may occur due to beta-blockade toxicity. Patient with airway disease may suffer severe asthma attacks. In addition, adverse effects of central nervous system include sedation, fatigue and sleep alterations might only occur with use of lipid soluble beta-blockers. Sexual dysfunction has been reported in some patients using the beta blockers^[8,9].

It has been shown in clinical studies that Beta-blocking agents have a preferential effect on beta₁ adrenoreceptors, mainly located in the cardiac muscle^[8,10,11]. Beta-blockers lessen cardiac contractility and heart rates by blocking myocardial beta-receptors, and therefore prevent exercise-induced increase in oxygen demands by the heart^[9]. Clinical pharmacology studies have confirmed that beta-blocking activity had enormous effect on the reduction in heart rate and cardiac output at rest and upon exercise, reduction of systolic blood pressure upon exercise, reduction of reflex orthostatic tachycardia and inhibition of isoproterenol-induced tachycardia^[8,10,11]. Therefore, beta-blockers are recommended to be administered prior to CCTA scanning. The purpose of this article is to provide an overview of the use of beta-blockers administration protocol for prospectively ECG-triggered CCTA.

PATIENT PREPARATION

There are several common indications for prospectively ECG-triggered CCTA inclusive of the CAD indications and non-CAD indications. CAD indications are inclusive of evaluation of coronary arteries in patients with new-onset heart failure to assess etiology, symptomatic patients at intermediate preset probability of CAD, patients with a chest pain syndrome regardless of acute or chronic with interpretable stress test. In certain circumstances, CCTA is required although non-CAD detection indications are presented such as suspected pulmonary embolism or aortic dissection or aneurysm, assessment of complex congenital heart disease, suspected coronary anomalies in symptomatic patients, evaluation of pulmonary vein anatomy prior to atrial fibrillation radiofrequency ablation, evaluation of cardiac venous anatomy prior to biventricular pacing and evaluation of cardiac mass or pericardial condition when non-radiation imaging modalities are limited^[12,13].

However, there are some contraindications to CCTA procedure which include pregnancy, severe anaphylactic contrast reaction, unable to comply with the scanning instructions such as fail to hold long breath-hold, renal insufficiency and clinically unstable patients^[12,13]. In addition, identification to contraindicated drug must be clarified before undergoing CCTA procedure inclusive of the pre-scan nitroglycerine such as severe aortic stenosis, hypertrophic cardiomyopathy and phosphodiesterase-5 (PDE-5) inhibitor and beta-blockers^[8,12]. For patients who are considered to undergo beta-blocker protocol, some guidelines have been suggested to avoid complications including screening contraindications to beta-blockers^[7]. The contraindications include sinus bradycardia, which is defined as a heart rate of < 60 bpm with systolic pressure of less than 100 mmHg; allergic to beta-adrenergic antagonists or its constituents; decompensated cardiac failure; asthma on beta-agonist inhalers; active bronchospasm; second or third-degree of atrioventricular (AV) block^[14-16]. Patients who are likely to have second- or third-degree AV block can be evaluated by generating a single-lead ECG strip^[7].

Patient's vital signs and pulse are also monitored and documented upon arrival. In patients with a sinus rhythm with heart rate < 65 bpm, no beta-blockers are required and therefore, the patient can be prepared for CCTA ex-

amination. In patients with irregular rhythm or/and higher heart rate (> 65 bpm), the beta-blockers are given according to the protocol setting (Figure 1).

In addition, patients are required to follow all standard instructions for contrast-enhanced studies including fasting for at least 4 h prior to the scan, maintaining oral hydration with clear fluid up to 1 h before scan and need to hold metformin for a minimum of 48 h following the scan. Patients with non-severe anaphylactic contrast reaction in the past should receive pre-medication treatment to avoid the risk of current contrast reaction. A pre-medication protocol suggested as 50 mg of prednisone is administered orally 13, 7 and 1 h prior to scan with additional of 50 mg oral diphenhydramine (*Benadryl*) is taken 1 h prior to scan^[12,17].

With regards to optimal heart rate control, caffeine product is not permitted within 12 h of CCTA. Moreover, severe hypotension can occur if PDE-5 inhibitors interact with nitrates. Therefore, patients are refrained from undertaking PDE-5 inhibitor drugs such as sildenafil (*Viagra*), vardenafil (*Levitra*) and tadalafil (*Cialis*) for at least 48 h before CCTA^[12,18,19]. However, usual cardiovascular medications are advisable to be taken continuously.

ADMINISTRATION OF BETA-BLOCKERS AND OTHER ALTERNATIVE DRUG IN HEART RATE-LOWERING THERAPY

Several cardio selective beta-blockers are available with distinct pharmacokinetic profiles such as acebutolol hydrochloride, atenolol, betaxolol hydrochloride, bisoprolol, esmolol, metoprolol succinate and metoprolol tartrate. However, metoprolol tartrate (*Lopressor*) was selected due to its convenient method of administration, dosage form availability and cardioselectivity^[7]. Unlike oral metoprolol tartrate, intravenous metoprolol dosage form is recommended due to its fast onset reaction (between 5 and 10 min) after administration. On the other hand, metoprolol tablets (oral) effect can only be seen within 1 hour after administration and the peak plasma concentrations are seen at 90 min. Although the onset reaction in both oral and IV routes differ significantly, the plasma half-life for metoprolol tartrate is similar in both oral and IV which ranges from 3 to 4 h in a healthy adult^[7,15,16].

Oral pre-medication in heart rate-lowering therapy is another alternative to achieve lower heart rate prior to the CT scanning. Pre-medicating the patient with tablet metoprolol gives an advantage which may reduce the risk of being injected with IV of metoprolol. However, without proper scanning arrangement, the effect of the oral metoprolol might not be effective and other factors such as anxiety and nervousness may also increase the patients' heart rate on the day of the examination. Thus, administration of metoprolol intravenously is most commonly performed prior to the CT scanning due to its fast onset and clinically feasibility.

Most previous practices injected their first bolus of metoprolol once the patient is lying down supine on the CT examination table. Our practice suggests that first bolus administration of metoprolol (2.5 mg) is given before the patient is brought on the CT examination table; right after the IV line is set (pre-procedure). Then, the patient's heart rate is monitored at the designated area under supervision of medically authorized personnel. This aims to avoid interruption of the procedure workflow and the delay time for beta-blockers to respond.

Although beta-blockers helped in lowering the heart rate, they also have negative inotropic effect and could decrease left ventricular contractility which may affect the assessment of ventricular function^[7]. However, ventricular function is only being evaluated by echocardiography or nuclear medicine studies and CCTA study is mainly performed for assessment of coronary arteries and degree of stenosis. Initially, two 2.5 mg doses of metoprolol are given with 5 min interval. Then two doses of 5 mg each are given 5 min apart with a total maximum dose of no more than 15 mg. Blood pressure and HR are monitored before each of the IV dose as stated in Figure 1. The beta-blockers' administration is conducted under the supervision of the radiologists or cardiologists. Blood pressure and continuous ECG monitoring should always be used when giving IV metoprolol.

Ivabradine is another attractive option to reduce patient heart rate for CCTA procedure^[20]. Unlike metoprolol, ivabradine selectively inhibits if current in sinoatrial node cells that controls the spontaneous diastolic depolarization, resulting in the reduction of diastolic depolarization rate and heart rate^[21,22]. Therefore, it is useful in patients in sinus rhythm, but not in other rhythms such as atrial fibrillation. Ivabradine lowers heart rate at concentrations that do not affect other cardiac ionic currents. Therefore, ivabradine has no other direct cardiovascular effect^[20]. Therefore, the main pharmacodynamics of ivabradine in humans is a specific dose-dependent reduction in heart rate. Heart rate reduction is achieved approximately 10 beats/min (bpm) at rest and during exercise at the recommended dosage (no more than 10 mg/d) which leads to a reduction in cardiac workload and myocardial oxygen consumption^[21]. Ivabradine has a relatively short half-life of around 2 h and is currently only available as an oral preparation.

HEART RATE CONTROL-LESS COMMONLY APPLIED IN 64- AND POST-64 CT

Heart rate control with use of medications is necessary in 4- and 16-slice CT, but less common in 64- and post-64 slice coronary CT angiography due to improvement in temporal resolution. Pache *et al.*^[23] in their early study showed that 64-slice CT has high diagnostic accuracy in the assessment of coronary artery bypass grafts, despite the presence of irregular or high heart rates. Recent tech-

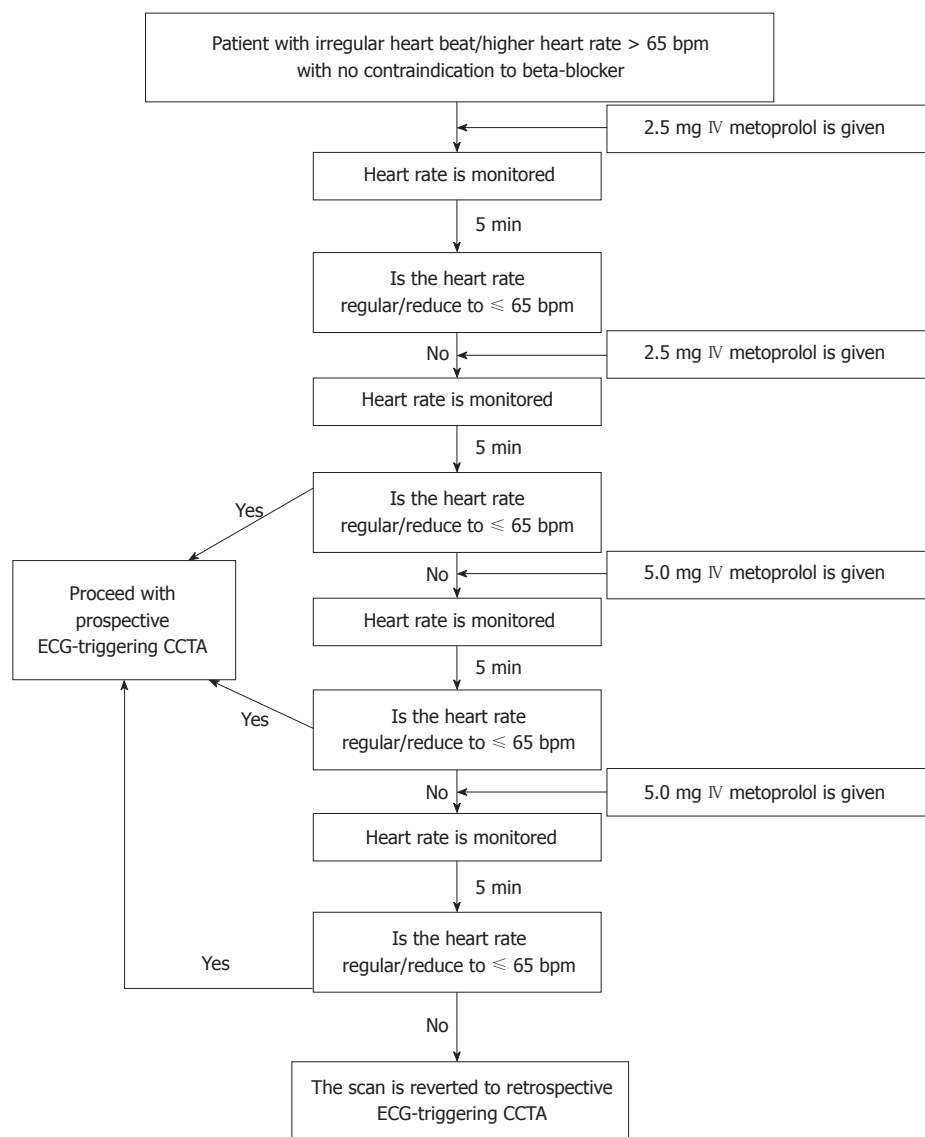


Figure 1 Flow chart showing the intravenous administration of metoprolol protocol in heart rate-lowering therapy. CCTA: Coronary computed tomography angiography.

nological developments with the introduction of dual-source CT and 320-slice CT have overcome the limitation of early generation of multislice CT as the temporal resolution was significantly increased, thus image quality and diagnostic value of coronary CT angiography was less dependent on heart rates^[24,25]. It has been reported that dual-source coronary CT angiography shows improved diagnostic performance in patients with a wide range of different heart rates being included^[26,27]. Expansion of multislice CT systems from a prototype 256-slice to a 320-slice system has allowed for acquisition of whole heart coverage in one gantry rotation. Studies have shown that 320-slice coronary CT angiography demonstrated high sensitivity and specificity at per-patient, per-vessel and per-segment analysis in patients with atrial fibrillation^[28-30]. These results indicate that 320-slice CT has the potential to broaden the use of coronary CT angiography to more patients with high or irregular heart rates or those without responding well to the heart rate

control.

POST-PROCEDURE CARE

All patients who are given IV metoprolol are observed for about 30 min once the scan is completed. If the patient presents with bronchospasm, an albuterol inhaler is given accordingly^[7,31]. If the patient's heart rate drops to less than 45 bpm, administration of atropine is considered. However, if the patient is resistant to the atropine while the heart rate drops continuously, resuscitative measures and IV administration of beta-agonists need to be administered such as dopamine or epinephrine^[7].

In general, beta-blockers are helpful in patients with irregular heart rate, either with premature atrial or ventricular contractions, supraventricular tachycardia and arrhythmias such as arterial fibrillation. With atrial fibrillation, the negative chronotropic and dromotropic effects of the beta-blockers lengthen the diastolic portion of the

cardiac cycle^[7,8]. In prospectively ECG-triggered CCTA, X-ray exposure occurs during a small portion of the cardiac cycle typically centered at mid-diastole at 75% of R-R interval^[1,6]. Therefore, increasing diastole by beta-blockers would improve CCTA image quality. Previous studies showed that the vessel visibility was achieved with the single-segment reconstruction in patients with low heart rates (< 65 bpm) and with multisegment reconstructions in patients with high heart rates (> 65 bpm)^[32,33]. Moreover, the visibility of right coronary artery also has been shown to improve significantly with the administration of beta-blockers. The proportion of the cardiac cycle spent in diastole increases as the heart rate decreases. Therefore, use of beta-blockers is suggested to increase the diastolic phase in the cardiac cycle^[34].

In conclusion, beta-blockers administration protocol has been discussed in this article with regard to its usefulness in preparing patient's heart rate for prospectively ECG-triggered CCTA. Since use of medication is essential to ensure that coronary CT angiography will provide excellent diagnostic images with few artifacts, understanding the mechanism of beta-blockers in cardiac imaging will contribute to the efficient use of coronary CT angiography technique in clinical diagnosis.

REFERENCES

- 1 Earls JP. How to use a prospective gated technique for cardiac CT. *J Cardiovasc Comput Tomogr* 2009; **3**: 45-51 [PMID: 19201376 DOI: 10.1016/j.jcct.2008.10.013]
- 2 Sabarudin A, Sun Z, Yusof AK. Coronary CT angiography with single-source and dual-source CT: comparison of image quality and radiation dose between prospective ECG-triggered and retrospective ECG-gated protocols. *Int J Cardiol* 2013; **168**: 746-753 [PMID: 23098849 DOI: 10.1016/j.ijcard.2012.09.217]
- 3 Sun Z, Lin C, Davidson R, Dong C, Liao Y. Diagnostic value of 64-slice CT angiography in coronary artery disease: a systematic review. *Eur J Radiol* 2008; **67**: 78-84 [PMID: 17766073 DOI: 10.1016/j.ejrad.2007.07.014]
- 4 Budoff MJ, Achenbach S, Blumenthal RS, Carr JJ, Goldin JG, Greenland P, Guerci AD, Lima JA, Rader DJ, Rubin GD, Shaw LJ, Wiegers SE. Assessment of coronary artery disease by cardiac computed tomography: a scientific statement from the American Heart Association Committee on Cardiovascular Imaging and Intervention, Council on Cardiovascular Radiology and Intervention, and Committee on Cardiac Imaging, Council on Clinical Cardiology. *Circulation* 2006; **114**: 1761-1791 [PMID: 17015792 DOI: 10.1161/CIRCULATIONAHA.106.178458]
- 5 Hoo J, Toh KH. First experience with 320-row multidetector CT coronary angiography scanning with prospective electrocardiogram gating to reduce radiation dose. *J Cardiovasc Comput Tomogr* 2009; **3**: 257-261 [PMID: 19577215 DOI: 10.1016/j.jcct.2009.05.013]
- 6 Efsthathopoulos EP, Kelekis NL, Pantos I, Brountzos E, Argentos S, Grebác J, Ziaka D, Katritsis DG, Seimenis I. Reduction of the estimated radiation dose and associated patient risk with prospective ECG-gated 256-slice CT coronary angiography. *Phys Med Biol* 2009; **54**: 5209-5222 [PMID: 19671974 DOI: 10.1088/0031-9155/54/17/009]
- 7 Pannu HK, Alvarez W, Fishman EK. Beta-blockers for cardiac CT: a primer for the radiologist. *AJR Am J Roentgenol* 2006; **186**: S341-S345 [PMID: 16714607 DOI: 10.2214/AJR.04.1944]
- 8 Trevor AJ, Katzung BG, Masters SB. *Katzung & Trevor's pharmacology: examination & board review*. 10th ed. New York: McGraw-Hill, 2005: 244-251
- 9 Choe JY. Drug actions and interactions. New York: McGraw-Hill Medical, 2011
- 10 Pérez-Schindler J, Philp A, Baar K, Hernández-Cascales J. Regulation of contractility and metabolic signaling by the β_2 -adrenergic receptor in rat ventricular muscle. *Life Sci* 2011; **88**: 892-897 [PMID: 21466811 DOI: 10.1016/j.lfs.2011.03.020]
- 11 Wachter SB, Gilbert EM. Beta-adrenergic receptors, from their discovery and characterization through their manipulation to beneficial clinical application. *Cardiology* 2012; **122**: 104-112 [PMID: 22759389 DOI: 10.1159/000339271]
- 12 Taylor CM, Blum A, Abbara S. Patient preparation and scanning techniques. *Radiol Clin North Am* 2010; **48**: 675-686 [PMID: 20705165 DOI: 10.1016/j.rcl.2010.04.011]
- 13 Hoffmann U, Ferencik M, Cury RC, Pena AJ. Coronary CT angiography. *J Nucl Med* 2006; **47**: 797-806 [PMID: 16644750]
- 14 Bostel CJ, Santoso B, Edwards LR. Drug benefits and risks international textbook of clinical pharmacology. Chichester: John Wiley & Sons, 2001
- 15 Hitner H, Nagle BT. Opioid (narcotic) analgesics, Pharmacology: an introduction. 5th ed. New York: McGraw-Hill, 2005
- 16 Burnham WM. Antiepileptic drugs (anticonvulsants). In: Kalant H, Roschlau WHE, editors. Principles of Medical Pharmacology. 5th ed. Philadelphia: B.C. Decker, 1989: 203-213
- 17 Marshall GD, Lieberman PL. Comparison of three pretreatment protocols to prevent anaphylactoid reactions to radiocontrast media. *Ann Allergy* 1991; **67**: 70-74 [PMID: 1859044]
- 18 Cheitlin MD, Hutter AM, Brindis RG, Ganz P, Kaul S, Russell RO, Zusman RM. ACC/AHA expert consensus document. Use of sildenafil (Viagra) in patients with cardiovascular disease. American College of Cardiology/American Heart Association. *J Am Coll Cardiol* 1999; **33**: 273-282 [PMID: 9935041 DOI: 10.1161/01.CIR.99.1.168]
- 19 Kloner RA, Hutter AM, Emmick JT, Mitchell MI, Denne J, Jackson G. Time course of the interaction between tadalafil and nitrates. *J Am Coll Cardiol* 2003; **42**: 1855-1860 [PMID: 14642699 DOI: 10.1016/j.jacc.2003.09.023]
- 20 Guaricci AI, Schuijff JD, Cademartiri F, Brunetti ND, Montrone D, Maffei E, Tedeschi C, Ieva R, Di Biase L, Midiri M, Macarini L, Di Biase M. Incremental value and safety of oral ivabradine for heart rate reduction in computed tomography coronary angiography. *Int J Cardiol* 2012; **156**: 28-33 [PMID: 21095627 DOI: 10.1016/j.ijcard.2010.10.035]
- 21 Murat SN, Orcan S, Akdemir R, Dogan M, Kara E, Balci M. Arrhythmic effects of ivabradine in patients with coronary artery disease. *Clin Invest Med* 2009; **32**: E322-E326 [PMID: 19796572]
- 22 Pichler P, Pichler-Cetin E, Vertesich M, Mendel H, Sochor H, Dock W, Syeda B. Ivabradine versus metoprolol for heart rate reduction before coronary computed tomography angiography. *Am J Cardiol* 2012; **109**: 169-173 [PMID: 22011557 DOI: 10.1016/j.amjcard.2011.08.025]
- 23 Pache G, Saueressig U, Frydrychowicz A, Foell D, Ghanem N, Kotter E, Geibel-Zehender A, Bode C, Langer M, Bley T. Initial experience with 64-slice cardiac CT: non-invasive visualization of coronary artery bypass grafts. *Eur Heart J* 2006; **27**: 976-980 [PMID: 16527826 DOI: 10.1093/eurheartj/ehi824]
- 24 Sun Z, Choo GH, Ng KH. Coronary CT angiography: current status and continuing challenges. *Br J Radiol* 2012; **85**: 495-510 [PMID: 22253353 DOI: 10.1259/bjr/15296170]
- 25 Sun Z. Multislice CT angiography in coronary artery disease: Technical developments, radiation dose and diagnostic value. *World J Cardiol* 2010; **2**: 333-343 [PMID: 21160611 DOI: 10.4330/wjc.v2.i10.333]
- 26 Brodoefel H, Burgstahler C, Tsiflikas I, Reimann A, Schroeder S, Claussen CD, Heuschmid M, Kopp AF. Dual-source CT: effect of heart rate, heart rate variability, and calcification on image quality and diagnostic accuracy. *Radiology* 2008; **247**: 346-355 [PMID: 18372455 DOI: 10.1148/radiol.2472070906]
- 27 Xu L, Yang L, Zhang Z, Li Y, Fan Z, Ma X, Lv B, Yu W. Low-dose adaptive sequential scan for dual-source CT coronary angiography in patients with high heart rate: comparison with

- retrospective ECG gating. *Eur J Radiol* 2010; **76**: 183-187 [PMID: 19595528 DOI: 10.1016/j.ejrad.2009.06.003]
- 28 **Pelliccia F**, Pasceri V, Evangelista A, Pergolini A, Barilla F, Viceconte N, Tanzilli G, Schiariti M, Greco C, Gaudio C. Diagnostic accuracy of 320-row computed tomography as compared with invasive coronary angiography in unselected, consecutive patients with suspected coronary artery disease. *Int J Cardiovasc Imaging* 2013; **29**: 443-452 [PMID: 22806317 DOI: 10.1007/s10554-012-0095-4]
- 29 **Pasricha SS**, Nandurkar D, Seneviratne SK, Cameron JD, Crossett M, Schneider-Kolsky ME, Troupis JM. Image quality of coronary 320-MDCT in patients with atrial fibrillation: initial experience. *AJR Am J Roentgenol* 2009; **193**: 1514-1521 [PMID: 19933642 DOI: 10.2214/AJR.09.2319]
- 30 **Uehara M**, Takaoka H, Kobayashi Y, Funabashi N. Diagnostic accuracy of 320-slice computed-tomography for detection of significant coronary artery stenosis in patients with various heart rates and heart rhythms compared with conventional coronary-angiography. *Int J Cardiol* 2013; **167**: 809-815 [PMID: 22429616 DOI: 10.1016/j.ijcard.2012.02.017]
- 31 **Salpeter SR**, Ormiston TM, Salpeter EE. Cardioselective beta-blockers in patients with reactive airway disease: a meta-analysis. *Ann Intern Med* 2002; **137**: 715-725 [PMID: 12416945 DOI: 10.7326/0003-4819-137-9-200211050-00035]
- 32 **Giesler T**, Baum U, Ropers D, Ulzheimer S, Wenkel E, Mennicke M, Bautz W, Kalender WA, Daniel WG, Achenbach S. Noninvasive visualization of coronary arteries using contrast-enhanced multidetector CT: influence of heart rate on image quality and stenosis detection. *AJR Am J Roentgenol* 2002; **179**: 911-916 [PMID: 12239036 DOI: 10.2214/ajr.179.4.1790911]
- 33 **Schroeder S**, Kopp AF, Kuettner A, Burgstahler C, Herdeg C, Heuschmid M, Baumbach A, Claussen CD, Karsch KR, Seipel L. Influence of heart rate on vessel visibility in noninvasive coronary angiography using new multislice computed tomography: experience in 94 patients. *Clin Imaging* 2002; **26**: 106-111 [PMID: 11852217 DOI: 10.1016/S0899-7071(01)00371-0]
- 34 **Boudoulas H**, Rittgers SE, Lewis RP, Leier CV, Weissler AM. Changes in diastolic time with various pharmacologic agents: implication for myocardial perfusion. *Circulation* 1979; **60**: 164-169 [PMID: 376175 DOI: 10.1161/01.CIR.60.1.164]

P- Reviewers: Di Bella G, Lin SL, Teragawa H
S- Editor: Zhai HH **L- Editor:** A **E- Editor:** Liu XM

