

Suprarenal fixation of endovascular aortic stent grafts: Assessment of medium-term to long-term renal function by analysis of juxtarenal stent morphology

Mark E. O'Donnell, DSEM, MRCS,^a Zhonghua Sun, PhD,^b R. John Winder, PhD,^c
Peter K. Ellis, MRCP, FRCR,^d Louis L. Lau, MD, FRCS,^a and Paul H. Blair, MD, FRCS,^a
Belfast and Ulster, United Kingdom; Perth, Western Australia

Objective: The effect of suprarenal stent fixation during endovascular aortic aneurysm repair (EVAR) on renal function remains unclear. A unique validated three-dimensional intraluminal imaging technique was used to analyze the effect of suprarenal stent position relative to renal artery orifices. Also analyzed was its medium-term to long-term effects on renal function.

Methods: The study cohort comprised 29 of 34 consecutive patients who underwent EVAR with the Zenith endograft system from September 1999 to March 2002 at a single institution. The precise locations of the uncovered suprarenal stent struts were assessed by a virtual endoscopic imaging technique. Anatomic and quantitative categorization of patients was made according to the configuration of uncovered stent struts across the renal artery ostia (RAO). The anatomic subgroups were defined as struts located centrally or peripherally across both RAO. The quantitative subgroups were defined as RAO crossed by multiple struts, a solitary strut, or no struts. The subgroups were compared for their renal function, as assessed by temporal measurements of serum creatinine concentration and creatinine clearance, and renal parenchymal perfusion defects, as assessed using contrast-enhanced computed tomography (CT).

Results: Mean follow-up was 52.7 months. Separate subgroup analysis for both anatomic and quantitative configurations did not demonstrate any significant difference in renal function between the different strut permutations ($P > .05$). Follow-up imaging confirmed one case of renal infarction secondary to an occluded accessory renal artery, although this patient had normal serum creatinine levels.

Conclusion: RAO coverage by suprarenal uncovered stents does not appear to have a significant effect on renal function as evaluated by creatinine measurements in patients with normal preoperative renal function. (*J Vasc Surg* 2007;45:694-700.)

Increasingly, suprarenal stent fixation is the preferred method of proximal endograft fixation in endovascular aneurysm repair (EVAR), especially when the proximal neck anatomy is less favorable because of short neck, angulation, concavity, thrombus, or calcification.¹⁻² Although renal dysfunction or failure as a direct consequence of suprarenal stent strut positioning across the renal artery has yet to be reported, longer-term renal effects of this technique are still unknown.³

It is postulated that renal dysfunction, when present after suprarenal stent fixation, is a multifactorial process. It

is not clear whether the proximal position of the stent struts across the renal artery ostia (RAO) causes an occlusive process that impairs blood flow or whether disruption of aortic thrombus and plaques from endovascular manipulations during device positioning and deployment causes microembolization that could potentially cause renal perfusion defects or infarcts.⁴ Neointimal hyperplasia around the stent may also exacerbate the occlusive process.⁵

The purpose of this study was to determine the medium-term to long-term effects on renal function of suprarenal stent fixation during EVAR in patients with normal preoperative renal function.

From the Departments of Vascular Surgery^a and Clinical Radiology,^d Royal Victoria Hospital; Health and Rehabilitation Sciences Research Institute, University of Ulster^c; and Department of Medical Imaging Science; and Curtin University of Technology.^b

Competition of interest: none.

Presented at the Northern Ireland Vascular Surgical Society Annual Meeting, Limavady, Sep 10, 2005 (Winner of Best Clinical Paper); The British Society of Interventional Radiology, Brighton, Nov 2-4, 2005; and The Society of Academic and Research Surgery, Edinburgh, Jan 11-13, 2006.

Reprint requests: Mark E. O'Donnell, DSEM, MRCSed, 42 Woodrow Gardens, Saintfield BT24 7WG UK (e-mail: modonnell904@hotmail.com).

0741-5214/\$32.00

Copyright © 2007 by The Society for Vascular Surgery.

doi:10.1016/j.jvs.2006.12.017

MATERIALS AND METHODS

Patient selection. Consecutive patients undergoing elective EVAR between September 1999 and March 2002 at a single institution were prospectively studied. Endovascular repair was offered to patients with suitable abdominal aortic aneurysm (AAA) anatomy who were high risk for open repair.⁶ Patients with a history of renal impairment or a preoperative serum creatinine level >130 mmol/L were excluded.⁷

The endograft used in this study was a standard preordered bifurcated endoluminal prosthesis based on the




Fig 1. Zenith self-expanding modular bifurcated aortic endograft with magnified view of the uncovered suprarenal stent struts.

Zenith system (William Cook Europe ApS, Bjaeverskov, Denmark). A self-expanding modular bifurcated aortic endograft with uncovered 2.5-cm-long suprarenal struts (Fig 1) for proximal fixation around the level of the renal arteries was placed using the standard transfemoral approach.⁸ All operations were performed by vascular surgeons and interventional radiologists who were proficient in EVAR.

Baseline demographic data, medical comorbidities, and risk factors were obtained for all patients. Serum creatinine concentration, aneurysm size, morphologic data, and the presence of any renal parenchymal perfusion defects were recorded both preoperatively and at each follow-up assessment. All postoperative sequelae, including any significant medical problems, were documented.

Assessment of renal function. Renal function was assessed by temporal measurements of serum creatinine (SCr) throughout the perioperative period and at subsequent outpatient reviews. Creatinine clearance was estimated using the Cockcroft-Gault formula⁹: Creatinine clearance = $[(140 - \text{age}) \times \text{weight}] / (\text{SCr} \times 72)$ for men and $[(140 - \text{age}) \times \text{weight}] / (\text{SCr} \times 85)$ for women.

Computed tomography assessment. Helical CT scans were obtained with a single-slice Philips AV-E1CT scanner (Philips Medical Systems, Eindhoven, The Netherlands) as per unit protocol (collimation, 5 mm; pitch, 1.0; reconstruction interval, 2 mm). Intravenous contrast medium (Omnipaque 300, Sandofi-Winthrop, New York, NY) was administered as a single uniphasic power injection at a rate of 2 to 3 mL/s to a total of 100 mL and a scan delay of 30 seconds. CT scans were completed on each patient preoperatively and postoperatively at 1 week, at 1, 3, 6, and 12 months, and annually thereafter.

A Toshiba 16 multislice CT scanner (Medical Imaging Systems, Kingsbury, UK) was installed in the Department of Radiology in 2004 and was used for CT scans later in the follow-up period. The scanning protocol for 16-slice CT was section thickness, 1.0 mm; pitch, 2.0; and a reconstruction interval of 1.0 mm.

The follow-up CT angiograms were used to determine maximal aneurysmal sac diameter, identify the presence of

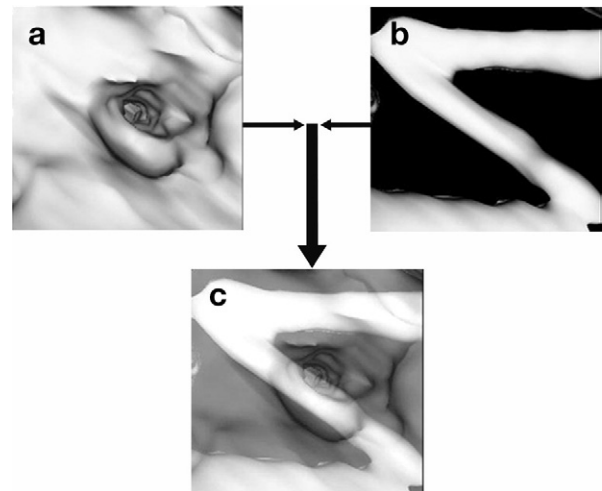


Fig 2. Helical computed tomography angiography formatted for three-dimensional postprocessing shows (a) intraluminal threshold view, (b) metallic stent threshold view, and (c) combined image demonstrating the stent strut crossing the luminal ostia.

endoleaks or stent migration, confirm the patency of the stent graft and renal arteries, and also to detect the presence of any renal parenchymal perfusion defects.

Assessment of stent struts in relation to renal artery ostia morphology. A novel, locally developed technique, virtual intravascular endoscopy (VIE), was used to assess the precise location of the uncovered suprarenal stent struts. All patients were given an intravenous contrast enhancement with a total volume of 100 mL administered at an injection rate of 2 mL/s and a scan delay of 30 seconds. Helical CT angiography was performed before and after stent grafting at a single-slice CT scanner with the scanning protocol of collimation, 5 mm; pitch, 1.0; and reconstruction interval, 2 mm. Poststent grafting CT angiography data sets were acquired within 1-week after stent graft implantation.

Virtual endoscopic images of the renal ostia and aortic stent struts were postprocessed in a workstation equipped with the commercial software Analyze 4.0 (Mayo Clinic, Rochester, Minn, or www.AnalyzeDirect.com). Generation of VIE images was subsequently determined by using a CT number thresholding technique. A CT number range was applied to generate optimal VIE images with fewer artifacts, which was identified by measuring the region of interest in the level of the renal arteries. The threshold range was measured in each patient because the degree of contrast enhancement differed with each individual (Fig 2).¹⁰

The VIE allowed the precise intraluminal position of the metal struts in relation to the aortic ostia to be assessed (Fig 3). This technique has been previously validated using both stent graft phantom models *in vitro* and *in vivo* patient studies.¹¹⁻¹³ Anatomic and quantitative categorization of patients was made according to the configuration of uncovered stent struts across the RAO. The anatomic subgroup

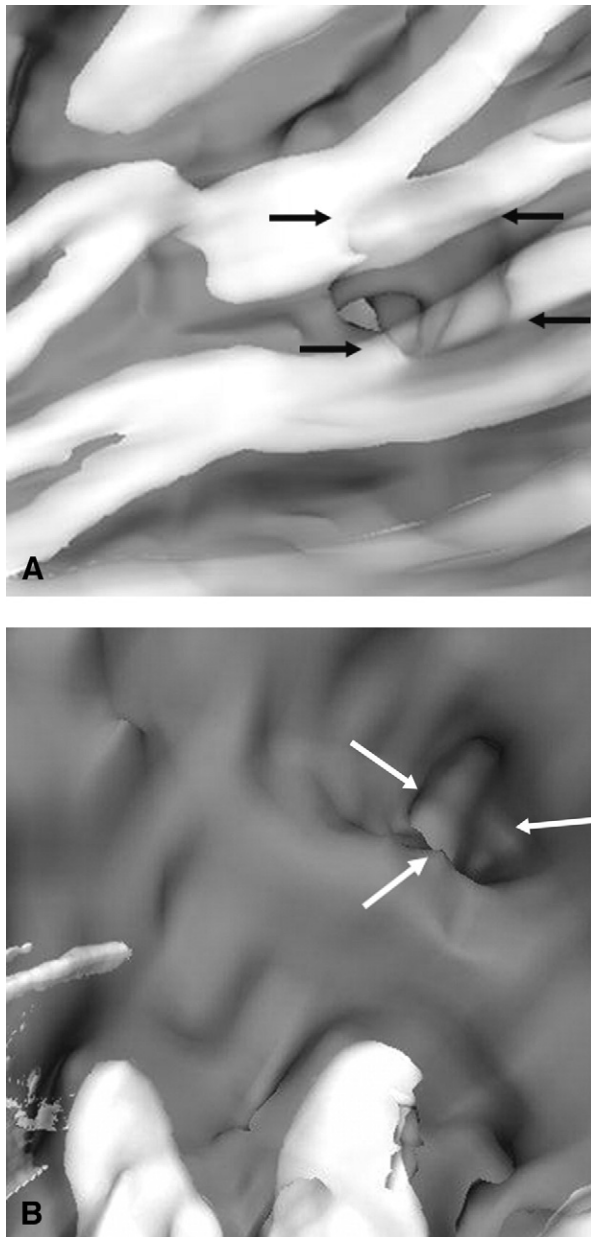


Fig 3. Virtual intravascular imaging. **A**, Peripheral encroachment of the renal artery ostia (stent struts shown by *black arrows*). **B**, No encroachment of the renal artery ostia (clear ostia shown by *white arrows*).

was defined as patients with struts located centrally or peripherally across both RAO. The quantitative subgroup was defined as patients with RAO crossed by multiple struts, a solitary strut, or no struts.

Statistical analysis. Normal distribution for study parameters was confirmed by histogram and Q-Q distribution plotting. Separate statistical analysis for anatomic and quantitative subgroups using analysis of variance for linear trend in both serum creatinine concentration and creatinine

Table. Patient demographics and operative and postoperative clinical data

	Men (n = 23)	Women (n = 6)
Preoperative		
Mean age, years (95% CI)	73.0 (69.7-76.3)	75.7 (68.9-82.5)
Body mass index	26.6	24.9
ASA	3.2	2.8
Medical history		
Hypertension	13	3
Congestive heart failure	2	0
Angina	8	1
MI	11	1
COPD	4	0
Diabetes	2	0
Smoking history		
Current	2	0
Former	15	2
Never	6	4
AAA diameter, mm (95% CI)	67.8 (62.5-73.2)	60.7 (54.8-66.6)
Operative		
Operative time (min)	194	155
Transfused blood (mL)	961	1375
Contrast infused (mL)	303	320
Blood loss (mL)	350	300
Postoperative		
Time in ICU (days)	0.4	0
Time to discharge (days)	11.1	8.7
Follow-up, months (range)	53.9 (6.6-79.6)	48.0 (13.5-77.6)
Alive	16	2

CI, Confidence interval; ASA, American Society of Anesthesiologists; MI, myocardial infarction; COPD, chronic obstructive pulmonary disease; AAA, abdominal aortic aneurysm; ICU, intensive care unit.

clearance was performed with SPSS 13 statistical software (SPSS Inc, Chicago, Ill). A paired sample *t* test was used to assess the creatinine trends and aneurysm size at separate postoperative time points compared with the preoperative baseline. All tests were two-tailed, with *P* < .05 considered significant.

RESULTS

Demographics. During the study period, 34 consecutive patients underwent EVAR. Five patients were excluded: four because of raised preoperative serum creatinine levels (1 with dialysis-dependant chronic renal failure, 1 with previous left nephrectomy for renal dysgenesis, 2 with moderate renal impairment), and one at 12 months because dialysis-dependant renal failure developed secondary to perforated sigmoid diverticular disease. Six women and 23 men were studied. The Table summarizes patient demographics and operative and postoperative clinical data.

Renal function. No episodes of acute renal failure occurred in the perioperative period. The VIE findings were used to categorize the stent struts in each of the 29 patients into two separate groups according to (1) the exact anatomic location and (2) the number of stent struts across

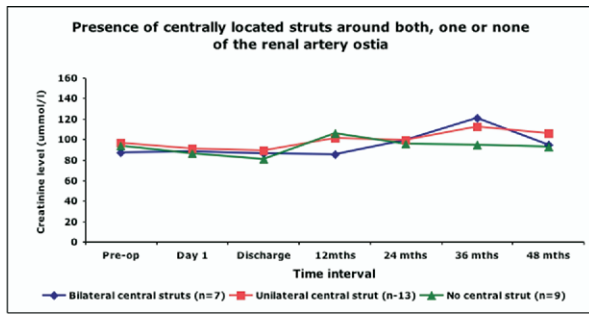


Fig 4. Analysis variance test for linear trend in serum creatinine concentration (mmol/L) for the anatomic configuration subgroup (presence of centrally located struts around one, both, or none of the renal artery ostia).

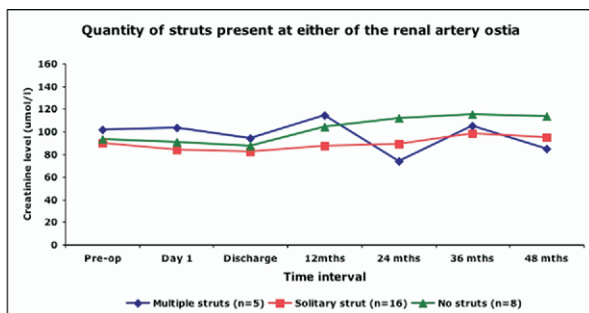


Fig 5. Analysis variance test for linear trend in serum creatinine concentration (mmol/L) for the quantitative configuration subgroup (quantity of struts present at either of the renal artery ostia).

each of the RAO. Analysis of variance for linear trend in serum creatinine concentration between different strut permutations for both these anatomic and quantitative configurations did not demonstrate any statistical significance ($P > .05$; Fig 4, Fig 5). Estimated creatinine clearance⁹ remained consistent with the serum creatinine levels and demonstrated no statistical difference between the different strut permutations.

Although there did not appear to be a significant difference in serum creatinine levels between the different stent strut groups, an overall trend of increasing creatinine levels, followed by improvement, was demonstrated over time when all patients were analyzed together as a group (+2.2 mmol/L maximal perioperative level, +10.1 mmol/L at 24 months, and +4.6 mmol/L at 36 months). This trend did not reach statistical significance ($P > .15$), however.

Computed tomography assessment. Preoperative CT imaging revealed two patients with accessory renal arteries. After EVAR, one of these patients sustained an infarct to the medial aspect of the lower pole of the left kidney, which was identified on the 1-week postoperative scan. Although a solitary central stent strut was identified across this patient's RAO on VIE, the infarct appeared to be secondary to an occlusion of a small accessory renal artery.

The other patient had an intact accessory renal artery and had no identifiable renal impairment on the CT scan. VIE confirmed the presence of a solitary peripheral stent strut across the RAO on that side. Both patients retained normal biochemical renal function in the postoperative period. VIE and CT follow-up imaging found no evidence of primary renal artery occlusion in any of the patients.

A type I endoleak was identified in one patient after a technically difficult procedure owing to poor quality of the infrarenal neck and an unusually wide origin of the left renal artery. This patient, unfortunately, died 13 months post-EVAR from hemorrhage caused by rupture secondary to this persisting endoleak, despite two subsequent therapeutic interventions including the placement of further covered extension (Cook) and Palmaz (Cordis Endovascular, Warren, NJ) fixation stents.

Five patients with type II endoleaks were identified postoperatively. Three patients had stable AAA size and were managed conservatively. Two patients had AAA expansion, and the endoleaks were treated with inferior mesenteric artery (IMA) coiling and thrombin-injection embolization, respectively. These endoleaks have persisted but remained stable, without any increase in AAA size on surveillance CT scans.

Two type III endoleaks were also identified. One patient had an endoleak identified at the proximal end of the first covered portion of the graft, which was thought to represent a type III endoleak arising from a tear in the endograft fabric rather than a type I endoleak. This was subsequently treated with the placement of a Zenith aortouniiliac system, and in one patient with a pre-existing type II endoleak, a dislocation developed at the left iliac limb that was treated successfully with the insertion of a limb extension.

As expected, there was a statistically significant reduction in maximal aneurysmal sac diameters over time compared with the preoperative baseline for all patients when analyzed together: -7.3% at 6 months, -15.6% at 12 months, -12.3% at 24 months, -24.0% at 36 months, and -18.7% at 48 months ($P < .05$).

Outcomes. Follow-up continued until March 2006 (mean, 52.7 months; range, 6.6 to 79.6 months) and was 100% complete for each patient. Eighteen patients (16 men, 2 women) remain well. Four patients died from cancer related illnesses (2 patients within the 12-month postoperative period), three from ischemic heart disease, and one from end-stage respiratory disease. Only one procedural-related death occurred, as documented previously, from a persisting type I endoleak. We were unable to trace the cause of death in the other two patients.

DISCUSSION

Suprarenal endograft fixation is increasingly common in EVAR, especially in patients who have suboptimal proximal aortic neck anatomy. Although early results are encouraging,¹⁴⁻²¹ the long-term effect of the placement of uncovered stent struts across the RAO remains unclear. Renal artery stenosis, inadvertent coverage of the renal

arteries, renal artery occlusion, transient increases in serum creatinine levels, and renal failure have all been reported after EVAR with suprarenal fixation.¹⁴⁻²² The exact cause of the renal impairment that presents after EVAR remains obscure, however. Various mechanisms have been suggested, but a combination of factors is most likely responsible.

Patients presenting for AAA surgery are often elderly, with multiple cardiovascular comorbidities such as ischemic heart disease, renovascular occlusive disease, or diabetes. Medical management of these conditions often requires a multitude of pharmacologic agents that may further compromise renal function. Progression of the atherosclerotic process may also predispose the patient to renal dysfunction. Tiao et al²³ reported an increase in creatinine levels, especially in the vascular age group of 60 to 80 years, and documented that after the age of 75 years, patients lose about 2% of creatinine clearance per year.

Contrary to a normal physiologic process, proponents of endovascular repairs for AAA have postulated various mechanisms that could account for renal dysfunction during the intraoperative and follow-up periods after EVAR. Thromboembolism during manipulation and placement of the endograft within the aortic neck and aneurysm sac caused by disruption of mural atheroma or thrombus may result in microembolization to the renal arteries. Kramer et al¹⁹ suggested an atheroembolic etiology after the identification of punctate renal infarcts on follow-up CT scans. The incidence of microembolization was also higher in patients undergoing EVAR compared with conventional open surgery.⁴ With modern endovascular grafting systems, however, procedural related manipulation is minimized, and therefore, a reduction in the disruption of thrombus should lead to a lower incidence of renal microembolism and subsequent functional impairment.

Contrast-induced nephrotoxicity during the procedure itself and follow-up CT surveillance has also been associated with an increased serum creatinine level.^{24,25} This deleterious effect may, however, be more significant in the short-term owing to a higher frequency of contrast-enhanced radiologic imaging. Greenberg et al²⁵ demonstrated an initial deterioration in renal function that stabilized at 12 months, followed by an improvement at 24 months. Our study concurred, with a maximal deterioration in renal function at 24 months, followed by an improvement at 36 months.

Considerable debate surrounds the potential occlusive effect of suprarenal stent struts across the RAO and whether this itself predisposes the patient to renal dysfunction or acts as an accelerant of the atherosclerotic process:

- Bove et al¹⁷ reported a progression of renal artery stenosis from 30% to 60% 12 months after endografting in one of eight patients with preoperative evidence of renal artery atherosclerotic disease and in another patient with normal preoperative renal arteries who developed >60% stenosis 1 month postoperatively.
- Lobato et al¹⁶ reported similar findings in one of five patients with pre-existing unilateral renal artery stenosis which progressed from >60% to 99% 4 months after suprarenal fixation.
- Lau et al²² reported that renal artery occlusion developed in two patients with pre-existing renal artery stenosis >50%.
- Marin et al,¹⁵ in contrast, reported an absence of disease progression after suprarenal endograft fixation in 18 patients with pre-existing significant renal artery stenosis.

Various imaging methods had been used to assess the renal arteries in these studies. Using VIE, a novel and more precise technique of revealing intraluminal encroachment of the RAO, we demonstrated that suprarenal endograft fixation does not produce significant renal artery occlusion or impair physiologic function as measured by serum creatinine concentration in patients with normal preoperative renal function.

The role of different stent types in the development of renal artery occlusion has also been reported. Birch et al²⁶ demonstrated a stent-dependant partial RAO occlusion secondary to the development of disorganized acellular matrix; however, these findings are based on a porcine model, and human ramifications are not yet clear. One study reported that approximately 15% to 30% of all adult patients have accessory renal arteries.²⁷ We report a prevalence of 6.9% (2/29 patients) in this study. Although one of these patients sustained a renal parenchymal infarct, there was no evidence of any abnormal biochemical sequelae. Karmacharya et al²⁸ report that the sacrifice of these accessory vessels does not necessarily lead to a detectable renal infarction, and even if it occurs, the insult seems to be well tolerated.

We do acknowledge various limitations. The 29 patients who were fully analyzed in this study only represent a small cohort of our endovascular experience (237 EVAR procedures to date). Although serum creatinine concentration is widely used as an indicator of renal function, it is not the most sensitive method for detecting renal dysfunction in patients. We recognize that renal artery stenosis, significant renal parenchymal tissue loss, and impaired glomerular filtration rate can be present before biochemical abnormalities are detected. Factors such as muscle mass and protein intake can also influence serum creatinine.²⁹⁻³⁰

An estimation of creatinine clearance using the Cockcroft-Gault formula⁹ was also used to account for the age, gender, and weight variations. This did not demonstrate any statistical significance between stent strut configurations.

The gold standard for monitoring renal function is the measurement of glomerular filtration rate (GFR); however, patient compliance for GFR is often poor. Serum cystatin C as a more accurate marker of GFR is well documented and may be appropriate for further studies because its concentration is not influenced by infections, liver diseases, or inflammatory diseases.³¹ It is also a more practical method

as it relies on a single serum sample without the inconvenience of a 24-hour collection of urine.³²

Although axial CT scanning is optimal for assessing aneurysm morphology and the presence of complications such as endoleaks, pseudoaneurysm formation, and even incidental pathologies, it may not be ideal for evaluation of renal artery anatomy and patency after EVAR. Several other methods for evaluation of renal artery stenosis may be appropriate as an adjunct in patient assessment, such as renal artery duplex ultrasonography,⁵ magnetic resonance angiography, and percutaneous angiography. However, unlike VIE, none of these methods are able to precisely identify the position of the stent struts across the RAO.

We also acknowledge that the initial CT scans were performed with a single-slice CT scanner, which resulted in suboptimal spatial resolution. This was the only available CT scanner within the Department of Radiology at that time. We did, however, validate the imaging quality of the single-slice CT scanner against a phantom plastic model aorta with a Zenith endograft deployed within the lumen.¹¹ This study confirmed the reliability of even the single-slice scanner in the localization of the stent struts. Scans performed with multislice CT (≥ 16 detector rows) are preferable to produce images with higher spatial resolution and better contrast enhancement in the abdominal aorta, which is especially useful for generation of three-dimensional images including VIE visualization.³³

Another limitation was the fixed scan delay used in our study. The automatic bolus tracking technique to maximize contrast enhancement in the arterial segments has become widely available in clinical practice, and this would be appropriate for future follow-up imaging.

Finally, we did not perform quantitative measurement of the cross-sectional area reduction of RAO by stent struts because our previous experience showed that VIE tends to overestimate the diameter of the stent struts across the RAO.³ Also, other published in vitro studies have demonstrated no significant effect of stent struts on the renal artery in terms of interference with blood flow or reduction of cross-sectional area.³⁴

CONCLUSION

This study demonstrates new insight into the anatomic position of the suprarenal stents across the RAO and their subsequent effects on renal function after EVAR surgery. VIE itself will probably not be warranted for preoperative imaging or diagnostics compared with axial CT images.¹³ However, the ability to provide high quality information on the three-dimensional relationship of the suprarenal stent struts to the aortic branch ostia is of interest in the follow-up of EVAR patients. Although VIE has already been widely described,^{3,11-13} this is the first report, to our knowledge, of the use of VIE imaging and its relationship to suprarenal stenting and renal function in the medium-term to long-term.

After review of the multiple permutations of stent struts based on the anatomic and quantitative configurations of struts at the ostia, we conclude that the RAO coverage by

suprarenal uncovered stents does not appear to have a significant effect on renal function as evaluated by creatinine measurements in patients with normal pre-operative renal function. Further evaluation of the use of VIE to assess the effects of stent migration and changes in strut morphology at the RAO over time in these patients is warranted.

AUTHOR CONTRIBUTIONS

Conception and design: MD, ZS, RW, PE, PB

Analysis and interpretation: MD, ZS, LL

Data collection: MD, ZS, RW

Writing the article: MD, LL, PB

Critical revision of the article: MD, ZS, RW, PE, LL, PB

Final approval of the article: MD, PE, LL, PB

Statistical analysis: MD

Obtained funding: ZS, RW, PE, PB

Overall responsibility: MD, PB

REFERENCES

1. Malina M, Lindh M, Ivancev K, Frennby B, Lindblad B, Brunkwall J. The effects of endovascular aortic stents placed across the renal arteries. *Eur J Vasc Endovasc Surg* 1997;13:207-13.
2. Ferko A, Krajina A, Jon B, Lesko M, Voboril Z, Zizka J, et al. Juxtarenal aortic aneurysm: endoluminal transfemoral repair? *Eur Radiol* 1997;7:703-7.
3. Sun Z, Zheng H. Cross-sectional area reduction of the aortic ostium by suprarenal stent wires: in vitro phantom study by virtual angiography. *Comput Med Imaging Graph* 2004;28:345-51.
4. Thompson MM, Smith J, Naylor AR, Sayers RD, Boyle JR, et al. Microembolization during endovascular and conventional aneurysm repair. *J Vasc Surg* 1997;25:179-86.
5. Kalliafas S, Travis SJ, Macierewicz J, Yusuf SW, Whitaker SC, Davidson I, et al. Intrarenal color duplex examination of aortic endograft patients with suprarenal stents. *J Endovasc Surg* 2001;8:592-6.
6. Chuter TA, Gordon RL, Reilly LM, Kerlan RK, Sawhney R, Jean-Claude J, et al. Abdominal aortic aneurysm in high-risk patients: short- to intermediate-term results of endovascular repair. *Radiology* 1999;210:361-5.
7. Walker SR, Yusuf SW, Wenham PW, Hopkinson BR. Renal complications following endovascular repair of abdominal aortic aneurysms. *J Endovasc Surg* 1998;5:318-22.
8. Görlich J, Kramer S, Tomczak R, Seifarth H, Merkle E, Sunder-Plassman L, et al. Thromboembolic complications after endovascular aortic aneurysm repair. *J Endovasc Ther* 2002;9:180-4.
9. Cockcroft DW, Gault MH. Prediction of creatinine clearance from serum creatinine. *Nephron* 1976;16:31-41.
10. Sun Z, Zheng H. Effect of suprarenal stent struts on the renal artery with ostial calcification observed on CT virtual intravascular endoscopy. *Eur J Vasc Endovasc Surg* 2004;28:534-42.
11. Sun Z, Winder J, Kelly B, Ellis P, Kennedy P, Hirst D. Influence of scanning parameters of single slice helical CT angiography on image quality of VIE: in vitro phantom study. *Comput Med Imaging Graph* 2004;28:3-12.
12. Sun Z, Winder RJ, Kelly BE, Ellis PK, Hirst DG. CT virtual endoscopy of abdominal aortic aneurysms treated with suprarenal endovascular stent grafting. *Abdom Imaging* 2003;28:580-7.
13. Sun Z, Winder RJ, Kelly BE, Ellis PK, Kennedy PT, Hirst DG. Diagnostic value of CT virtual intravascular endoscopy in aortic stent-grafting. *J Endovasc Ther* 2004;11:13-25.
14. Malina M, Brunkwall J, Ivancev K, Lindh M, Lindblad B, Risberg B. Renal arteries covered by aortic stents: clinical experience from endovascular grafting of aortic aneurysms. *Eur J Vasc Endovasc Surg* 1997;14:109-13.
15. Marin ML, Parsons RE, Hollier LH, Mitty HA, Ahn J, Parsons RE, et al. Impact of transrenal aortic endograft placement on endovascular

- graft repair of abdominal aortic aneurysms. *J Vasc Surg* 1998;28:638-46.
16. Lobato AC, Quick RC, Vaughn PL, Rodriguez-Lopez J, Douglas M, Diethrich EB. Transrenal fixation of aortic endografts: intermediate follow-up of a single-center experience. *J Endovasc Ther* 2000;7:273-8.
 17. Bove PG, Long GW, Zelenock GB, Bendick PJ, Khoury MD, Burr MO, et al. Transrenal fixation of aortic stent-grafts for the treatment of infrarenal aortic aneurysmal disease. *J Vasc Surg* 2000;32:697-703.
 18. Kichikawa K, Uchida H, Maeda M, Ide K, Kubota Y, Sakaguchi S, et al. Aortic stent-grafting with transrenal fixation: use of newly designed spiral Z-stent endograft. *J Endovasc Ther* 2000;7:184-91.
 19. Kramer SC, Seifarth H, Pamler R, Fleiter T, Buhring J, Sunder-Plassmann L, et al. Renal infarction following endovascular aortic aneurysm repair: incidence and clinical consequences. *J Endovasc Ther* 2002;9:98-102.
 20. Burks JA Jr, Faries PL, Gravereaux EC, Hollier LH, Marin ML. Endovascular repair of abdominal aortic aneurysms: stent-graft fixation across the visceral arteries. *J Vasc Surg* 2002;35:109-13.
 21. Abraham CZ, Chuter TA, Reilly LM, Okuhn SP, Pethan LK, Kerlan RB, et al. Abdominal aortic aneurysm repair with the Zenith stent graft: short to midterm results. *J Vasc Surg* 2002;36:217-24;discussion 224-5.
 22. Lau LL, Hakaim AG, Oldenburg WA, Neuhauser B, McKinney JM, Paz-Fumagalli R, et al. Effect of suprarenal versus infrarenal aortic endograft fixation on renal function and renal artery patency: a comparative study with intermediate follow-up. *J Vasc Surg* 2003;37:1162-8.
 23. Tiao JYH, Semmens JB, Masarei JRL, Lawrence-Brown MMD. The effect of age on serum creatinine levels in an aging population: relevance to vascular surgery. *Cardiovasc Surg* 2002;10:445-51.
 24. Carpenter JP, Fairman RM, Barker CF, Golden MA, Velazquez OC, Mitchell ME, et al. Endovascular AAA repair in patients with renal insufficiency: strategies for reducing adverse renal events. *Cardiovasc Surg* 2001;9:559-64.
 25. Greenberg RK, Chuter TA, Lawrence-Brown M, Haulon S, Nolte L; Zenith Investigators. Analysis of renal function after aneurysm repair with a device using suprarenal fixation (Zenith AAA Endovascular Graft) in contrast to open surgical repair. *J Vasc Surg* 2004;39:1219-28.
 26. Birch PC, Start RD, Whitbread T, Palmer I, Gaines PA, Beard JD. The effects of crossing porcine renal artery with various endovascular stents. *Eur J Vasc Endovasc Surg* 1999;17:185-90.
 27. Kabalin JN. Surgical anatomy of retroperitoneum, kidneys and ureters. In: Walsh PC and Retick, editors. *Campbell's urology*. 8th ed. Philadelphia, PA: Saunders; 2002. p. 27-31.
 28. Karmacharya J, Parmer SS, Antezana JN, Fairman RM, Woo EY, Velazquez OC, et al. Outcomes of accessory renal artery occlusion during endovascular aneurysm repair. *J Vasc Surg* 2006;43:8-13.
 29. Levey AS, Perrone RD, Madias NE. Serum creatinine and renal function. *Annu Rev Med* 1988;39:465-90.
 30. Shemesh O, Golbetz H, Kriss JP, Myers BD. Limitations of creatinine as filtration marker in glomerulopathic patients. *Kidney Int* 1985;28:830-36.
 31. Villa P, Jiménez M, Soriano MC, Manzanares J, Casasnovas P. Serum cystatin C concentration as a marker of acute renal dysfunction in critically ill patients. *Crit Care* 2005;9:R139-43.
 32. Finney H, Newman DJ, Gruber W, Merle P, Price CP. Initial evaluation of cystatin C measurement by particle-enhanced immunonephelometry on Behring nephelometer system (BNA, BN II). *Clin Chem* 1997;43:1016-22.
 33. Rydberg J, Kopecky KK, Lalka SG, Johnson MS, Dalsing MC, Persohn SA. Stent grafting of abdominal aortic aneurysms: Pre- and postoperative evaluation with multislice helical CT. *J Comput Assist Tomogr* 2001;25:580-6.
 34. Liffman K, Lawrence-Brown MM, Semmens JB, Sutalo ID, Bui A, White F, et al. Suprarenal fixation: effect on blood flow of an endoluminal stent wire across an arterial orifice. *J Endovasc Ther* 2003;10:260-274.

Submitted Sep 10, 2006; accepted Dec 8, 2006.