

Research

***Corresponding author**
Zhonghua Sun, PhD, FSCCT
 Professor
 Department of Medical Radiation Sciences
 School of Science
 Curtin University
 GPO Box, U1987, Perth
 Western Australia 6845, Australia
 Tel. +61-8-9266 7509
 Fax: +61-8-9266 2377
 E-mail: z.sun@curtin.edu.au

Volume 3 : Issue 1

Article Ref. #: 1000HROJ3131

Article History

Received: August 19th, 2016

Accepted: September 8th, 2016

Published: September 8th, 2016

Citation

Sun Z, Lee S-Y. Diagnostic value of coronary CT angiography with use of left coronary bifurcation angle in coronary artery disease. *Heart Res Open J.* 2016; 3(1): 19-25. doi: [10.17140/HROJ-3-131](https://doi.org/10.17140/HROJ-3-131)

Copyright

©2016 Sun Z. This is an open access article distributed under the Creative Commons Attribution 4.0 International License (CC BY 4.0), which permits unrestricted use, distribution, and reproduction in any medium, provided the original work is properly cited.

Diagnostic Value of Coronary CT Angiography With Use of Left Coronary Bifurcation Angle in Coronary Artery Disease

Zhonghua Sun, PhD, FSCCT^{1*}; Shen-Yuan Lee, MSc²

¹Department of Medical Radiation Sciences, Curtin University, GPO Box U1987, Perth, Western Australia 6845, Australia

²Department of Medical Imaging and Radiological Science, Central Taiwan University of Science and Technology, Taichung 40601, Taiwan

ABSTRACT

Background: Atherosclerosis generally occurs in the blood vessels with angulation or curvature, however, association between coronary bifurcation angle and coronary artery disease needs to be further clarified when compared to normal patients.

Objectives: The aim of this study is to determine the relationship between left coronary bifurcation angle and development of coronary artery disease when compared to patients with normal coronary arteries.

Methods: Fifty patients (40 men, mean age, 55.2 years) who underwent coronary computed tomography (CT) angiography for clinical diagnosis of coronary artery disease were included in the study. Of these patients, coronary plaques were present at one or more coronary arteries in 25 patients, while in the remaining 25 cases, no plaque was detected at the coronary arteries, thus serving as the control group. Left coronary bifurcation angle between left anterior descending and left circumflex was measured on 3D volume rendering images by two assessors with $>80^\circ$ as the cut-off value to determine significant stenosis.

Results: The mean bifurcation angle was $72.9^\circ \pm 19.4^\circ$ (range, 36° , 112°) among 50 patients. The mean bifurcation angle was significantly wider in patients with coronary plaques than that measured in patients with normal coronary artery ($p < 0.001$), with corresponding values being $83.9^\circ \pm 17.5^\circ$ (range, 45° , 112°) and $62.5^\circ \pm 15.4^\circ$ (range, 36° , 89°). Of 25 patients with coronary plaques, 18 (72%) had a bifurcation angle $>80^\circ$, while only 12% of the patients had a bifurcation angle $>80^\circ$ in the control group.

Conclusion: This study further confirms the direct relationship between left coronary bifurcation angle and development of coronary artery disease with diseased coronary arteries associated with wider angulation.

KEYWORDS: Bifurcation angle; Coronary artery disease; Coronary CT angiography; Coronary plaque; Measurement.

ABBREVIATIONS: CT: Computed Tomography; CCTA: Coronary Computed Tomography Angiography; PPV: Positive Predictive Value; DICOM: Digital Imaging and Communications in Medicine; LAD: Left Anterior Descending; LCx: Left Circumflex; VR: Volume Rendering; SNR: Signal-To-Noise Ratio.

INTRODUCTION

Coronary computed tomography angiography (CCTA) has been widely accepted as a less-invasive imaging modality with high diagnostic value in the diagnosis of coronary artery disease due to rapid technological developments in multislice CT scanners.¹⁻⁵ While radiation dose associated with CCTA has been significantly reduced with use of various dose-reduction strat-

egies, the limitations of CCTA lie in two aspects: inferior temporal resolution and effect of heavily calcified plaques on the reliable detection of coronary stenosis. The temporal resolution of current multislice CT scanners is between 83 and 175 ms, thus, use of beta-blockers is necessary to control heart rate in most of the patients with heart rate >70 beats per minute, although high diagnostic value of CCTA in patients with high heart rates has been reported in some recent studies using latest CT scanners.⁶⁻¹⁰ It is well known that high calcification or high calcium score in the coronary arteries results in false positive results, thus leading to low specificity and positive predictive value (PPV).¹¹⁻¹⁵ This limitation has been addressed to some extent with use of image processing methods as reported in some studies.¹⁶⁻¹⁸

Another approach to improve diagnostic value of CCTA in the diagnosis of calcified plaques is to use left coronary bifurcation angle as opposed to the conventional method of measuring coronary lumen stenosis. Recent studies have shown that diagnostic accuracy of CCTA has been significantly augmented with use of bifurcation angle as a criterion to determine coronary stenosis when compared to assessment of the degree of lumen stenosis.¹⁹⁻²¹ Despite these promising results, it is still necessary to clarify the role of bifurcation angle in both normal and diseased coronary arteries. Thus, the purpose of this study is to further clarify the clinical value of CCTA with use of left coronary bifurcation angle in the diagnosis of coronary artery disease. We hypothesized that wider angulation is associated with higher prevalence of coronary plaques when compared to the normal coronary arteries.

METHODS

Study Population

This retrospective study involves reviewing consecutive patients who underwent CCTA examination for diagnostic assessment of coronary artery disease. Eligible criteria included successful completion of CCTA scans with good image quality for demonstration of coronary arteries. Patients were excluded if they had known allergy to contrast medium, prior history of coronary stenting or coronary artery bypass surgery, impaired renal function or unable to control heart rate less than 65 beats per minute after beta-blockers were administered. Fifty-one patients met our selection criteria and were included in the analysis with good image quality allowing analysis of normal coronary anatomy and coronary plaques. The bifurcation angle could not be detected in one patient due to anomaly of the left circumflex which arose from the ascending aorta posterior to the right coronary artery. Therefore, our final data included 50 cases (40 men, mean age, 55.2±8.4 years) with 25 having coronary artery disease with at least one plaque present at one of the coronary arteries, and another 25 without having any plaque at the coronary arteries, so these 25 cases served as the control group.

Ethical approval from Institutional Review Board (IRB) was waived in this study since CCTA image acquisition was part of the clinical referral for diagnosis of coronary artery

disease. Due to retrospective nature of this study, there is no need for obtaining informed consent from the patients.

CCTA Scanning Protocols

All patients were scanned with second generation dual-source 128-slice CT (Siemens Definition Flash, Siemens Healthcare, Forchheim, Germany) and 256-slice CT scanners (Brilliance iCT, Philips Healthcare, Cleveland, OH, USA), with the following imaging protocols: detector collimation 2×64×0.6 mm, gantry rotation of 0.28 s, with a tube voltage of 120 kVp for Siemens scanner, and 2×128×0.625 mm with a dynamic z-focal spot, gantry rotation of 0.27s, with a tube voltage of 120 kVp for Philips iCT, respectively. All scans were performed with retrospective ECG gating with images targeting a diastolic phase at 75% of R-R interval. Beta-blockers were administered in patients with heart rate >65 beats per minute prior to the CT scans. In all examinations, non-ionic contrast medium Ultravist 370 mg/ml (Ultravist 370, Bayer Schering Pharma AG, Taipei, Taiwan) was delivered using a dual-head power injector. The scan was initiated with use of bolus tracking technique with a CT attenuation of 120 HU as the triggering threshold in the ascending aorta. Forty-five to 55 ml contrast medium was injected at an injection rate of 3.0 ml/s followed by a saline flush of 30-40 ml. Pitch ranged from 0.2-0.4. Images were reconstructed with a slice thickness of 0.6-0.625 mm and a reconstruction interval of 0.3-0.33 mm resulting in the voxel size ranging from 0.30x0.30x0.30 mm³ to 0.33x0.33x0.33 mm³.

Image Analysis and Measurement of Bifurcation Angle

CCTA images in digital imaging and communications in medicine (DICOM) format were transferred to a separate workstation equipped with Analyze V 12.0 software (AnalyzeDirect, Inc., Lexana, KS, USA) for image post-processing and analysis. Analyze is a biomedical software enabling robust analysis of medical images including various views consisting of 2D and 3D reconstructed images and 3D virtual intravascular endoscopic visualizations.²¹⁻²³

Left main bifurcation angle between left anterior descending (LAD) and left circumflex (LCx) was measured to determine the correlation between bifurcation angle and coronary plaques. Three-dimensional (3D) volume rendering (VR) images reconstructed from 2D axial CCTA were used to measure the bifurcation angle between LAD and LCx (Figure 1). Measurements were performed by two assessors independently. Three consecutive measurements of the bifurcation angle were obtained in each case with the mean value taken as final to minimize biased results. In addition to the bifurcation angle measurement, assessors analyzed the coronary plaque characteristics in terms of plaque composition, such as calcified, non-calcified or mixed plaques, as well as plaque distribution in the coronary arteries. The inter-observer agreement and intra-observer agreement was good with 95% and 91%, respectively. A degree of >80° bifurcation angle is used as a cut-off value to determine significant coronary artery disease or stenosis, according to pre-

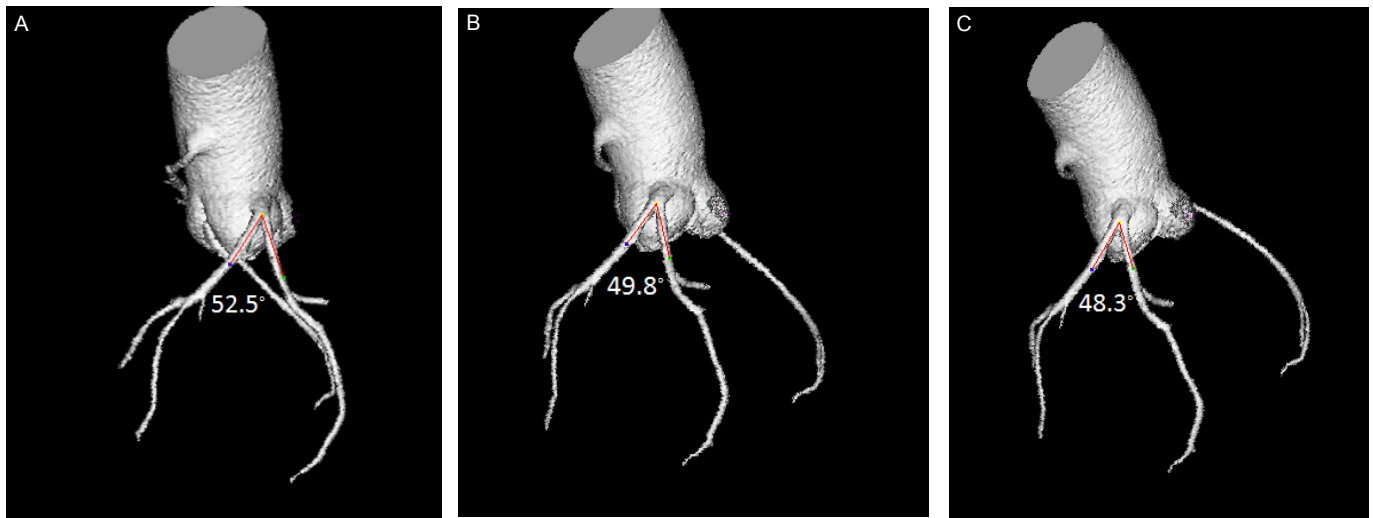


Figure 1: Three-dimensional (3D) volume rendering shows the bifurcation angle of the left main coronary artery as it branches into the left anterior descending (LAD) and left circumflex (LCx). Measurement of the angle was performed three times on 3D volume rendered images at different positions in a 56-year-old woman with the mean angle of 50.2°.

vious studies.¹⁸⁻²¹

Statistical Analysis

Statistical analysis were performed using SPSS 24.0 (SPSS Inc, Chicago, IL, USA). Continuous variables were expressed as mean±standard deviation, while categorical variables were presented as percentages. Chi-square test was used for categorical variables between the two groups (or Fisher's Exact test was used if the variable or an event was observed in less than 5 cases). Comparison was performed using one sample *t*-test. A *p* value of <0.05 was considered statistically significant.

RESULTS

CCTA was successfully performed in all patients with no complications. Of 50 cases, image quality was found good or excellent in 48 cases with the mean CT attenuation more than 300 HU (Hounsfield unit) or signal-to-noise ratio (SNR) more than 10 in the ascending aorta or coronary artery. In the remaining 2 cases, CT attenuation was lower than 160 HU in one case, and high

standard deviation in another case resulting in low SNR (7.8). Table 1 shows patient's characteristics and plaque distribution in the coronary arteries.

The mean bifurcation angle was measured 72.9°±19.4° (range, 36°,112°) among all 50 patients (25 in the group with normal coronary artery and 25 in the group with coronary plaques). The mean bifurcation angle in patients with coronary plaques was measured 83.9°±17.5° (range, 45°,112°), and this is significantly wider than that measured in patients with the normal coronary artery, which was 62.5°±15.4° (range, 36°,89°) (*p*<0.001) (Table 1). Of 25 patients with coronary plaques, 18 (72%) had a bifurcation angle >80°, while in contrast, only 12% of the patients had a bifurcation angle >80° in the control group. Of 25 cases with coronary plaques, most of them were found to be calcified (84%), while mixed plaques were noted in 4 cases.

Figure 2 is an example of a patient with calcified plaques at the left anterior descending coronary artery with wide angulation, while Figure 3 shows a narrow angulation in a patient with normal coronary arteries.

Parameters for comparison	Study group (25)	Control group (25)
Mean age±SD*	58.3±6.0	52.2±9.4
Mean angle±SD*	83.9±17.1	62.5±15.4
Gender: M:F	22:3	18:7
Plaque distribution (%)	LAD: 44% LCx: 4% RCA: 4% 2-vessel disease: 24% 3-vessel disease: 24%	N/A
No. of cases in relation to age group (years)	41-50: 8% 51-60: 64% 61-70: 24% 71-80: 4%	N/A

LAD-left anterior descending, LCx-left circumflex, RCA-right coronary artery, N/A-not applicable, SD-standard deviation.

*indicates significant difference (*p*<0.05)

Table 1: Patient characteristics and plaque distribution.

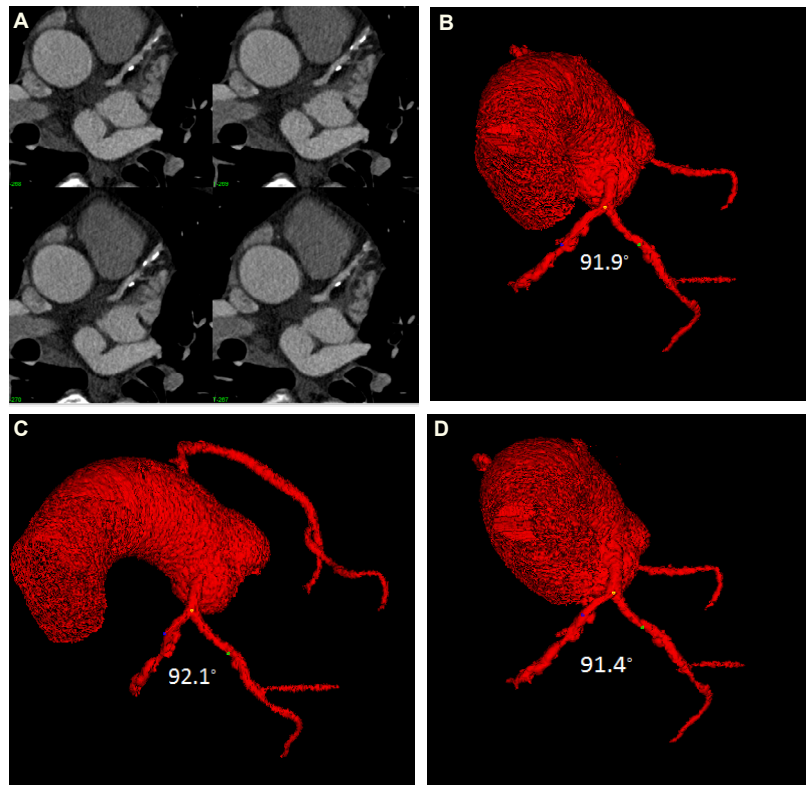


Figure 2: Association between wide angulation and coronary artery disease in a 52-year-old man with coronary artery disease. A: 2D axial images show multiple calcified plaques at the left anterior descending artery. B-D: Left coronary bifurcation angle between LAD and LCx was measured at three different positions with the mean angulation of 91.8° indicating significant coronary stenosis.

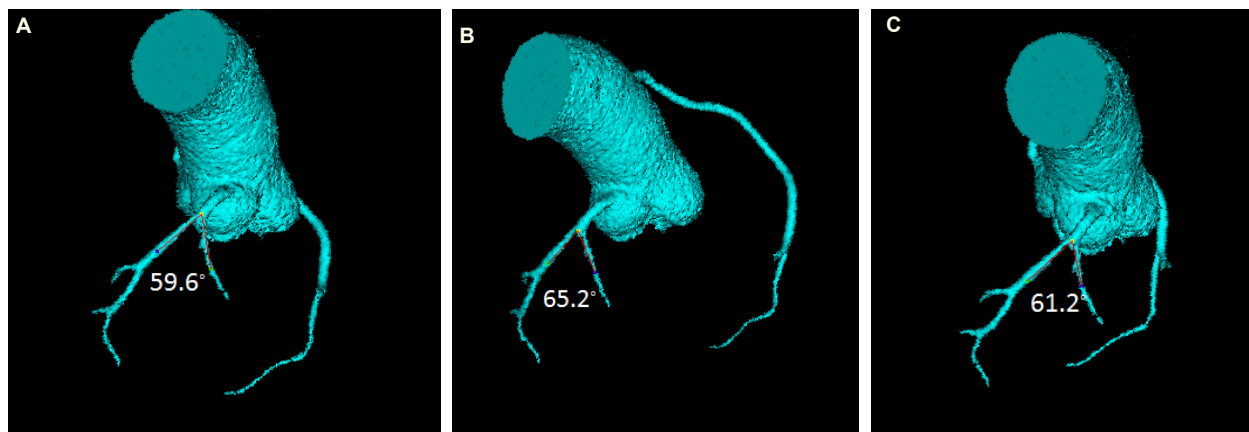


Figure 3: Association between narrow angulation and normal coronary artery in a 55-year-old woman. A-C: Left coronary bifurcation angle between LAD and LCx was measured at three different positions with the mean angle of 62° indicating no significant coronary disease.

DISCUSSION

This study further clarifies the accuracy of using left coronary bifurcation angle to determine coronary artery disease. Results of this study showed that patients with coronary artery plaques are associated with wider angulation, while narrower angulation is seen in patients with normal coronary arteries. Therefore, based on current available literature, while waiting for additional large studies evaluating the prognostic role of this parameter, the analysis of bifurcation angle measurement, especially for left main, may be considered during the routine diagnostic assess-

ment of coronary artery disease.

The rationale of measuring coronary bifurcation angle is because of the relationship between hemodynamic changes and atherosclerotic development at bifurcation regions. Both clinical studies and hemodynamic analysis using computer modelling have shown that plaques usually occur in the vascular areas with angulation or abrupt curvatures.²⁴⁻²⁹ Our early report showed a direct correlation between left coronary bifurcation angle and coronary diameter changes with significantly wider angle and larger diameter in diseased coronary arteries when

compared to the normal ones.³⁰ This has been confirmed by a recent study investigating the association between bifurcation angle and risk factors of developing coronary artery disease.³¹ Based on analysis of 196 patients with suspected coronary artery disease, Temov and Sun concluded that male patients and patients with large body mass index were more than 2-fold likely to have wider angulation ($>80^\circ$) with associated higher risk of coronary artery disease. This study further highlights the additional value of using bifurcation angle for diagnosis of coronary artery disease through a direct comparison between diseased patients and the normal ones.

Using bifurcation angle as a diagnostic parameter has also been shown to improve the diagnostic value of CCTA in the detection of calcified plaques. Low diagnostic specificity and PPV of CCTA in calcified plaques is mainly due to high false positive rates caused by blooming artifacts which result from heavy calcification in the coronary arteries.¹¹⁻¹⁵ This is a widely known limitation of CCTA. Some recent studies have addressed this issue by showing the improved diagnostic performance of CCTA with use of bifurcation angle measurement when compared to the conventional approach based on coronary lumen stenosis.^{19,20} The specificity and PPV were improved from 33% and 43% to 79% and 81%, corresponding to CCTA by coronary lumen diameter and bifurcation angle measurements, respectively.¹⁹ Although diagnostic value of CCTA was not assessed in this study due to inclusion of low to intermediate pretest probability of coronary artery disease without having invasive coronary angiography as the reference standard, findings are consistent with these previous reports showing the improved accuracy of CCTA using bifurcation angle.

Although this is a retrospective study based on a small number of cases, results through a direct comparison between two groups add valuable information to the existing studies. Findings of this study further strengthen the previous reports that left coronary bifurcation angle is a more accurate method for determining significant coronary stenosis than coronary lumen assessment. However, some limitations in this study should be acknowledged. First, a small sample size is one of the main limitations. Inclusion of more patients, especially with more clinical centers' involvement would be desirable to allow us draw robust conclusions. Second, as discussed above, there is no correlation of CCTA findings with invasive coronary angiography, therefore, no diagnostic value is available. Further, due to the retrospective nature, risk factors associated with coronary artery disease are not available in most of the patients in this study. However, the association between common risk factors and coronary artery disease has been well studied in a recently published study.³¹ Finally, although plaque distribution and type of plaque were analyzed, due to limited number of cases, there is no analysis of plaque features, in particular, analysis of plaque composition such as low-attenuating plaque, plaque volume and length which are commonly used to indicate the plaque vulnerability.^{28,32} Thus, further studies should focus on the analysis of these features in relation to their association with bifurcation

angle measurement.

In conclusion, this study further confirms the relationship between left coronary bifurcation angle and coronary artery disease with diseased coronary artery associated with wider angulation when compared to the normal coronary arteries. Further research is required to investigate the plaque composition in relation to the bifurcation angle with the aim of identifying high-risk plaque or plaque vulnerability, preferably to be conducted at multicenter sites with inclusion of more patients.

CONFLICTS OF INTEREST

The authors declare that they have no conflicts of interest.

REFERENCES

1. Sun Z, Cao Y, Li HF. Multislice computed tomography angiography in the diagnosis of coronary artery disease. *J Geriatr Cardiol.* 2011; 8: 104-113. doi: [10.3724/SP.J.1263.2011.00104](https://doi.org/10.3724/SP.J.1263.2011.00104)
2. Sun Z, Choo GH, Ng KH. Coronary CT angiography: Current status and continuing challenges. *Br J Radiol.* 2012; 85: 495-510. doi: [10.1259/bjr/15296170](https://doi.org/10.1259/bjr/15296170)
3. Sun Z, Lin C. Diagnostic value of 320-slice coronary CT angiography in coronary artery disease: A systematic review and meta-analysis. *Curr Med Imaging Rev.* 2014; 10: 272-280. Web site. <http://www.ingentaconnect.com/content/ben/cmjr/2014/00000010/00000004/art00008>. Accessed August 18, 2016
4. Pelliccia F, Pasceri V, Evangelista A, et al. Diagnostic accuracy of 320-row computed tomography as compared with invasive coronary angiography in unselected, consecutive patients with suspected coronary artery disease. *Int J Cardiovasc Imaging.* 2013; 29: 443-452. doi: [10.1007/s10554-012-0095-4](https://doi.org/10.1007/s10554-012-0095-4)
5. Funabashi N, Namihira Y, Irie R, et al. Recommended acquisition parameters in achieving successful evaluation of coronary lumen patency surrounded by XIENCE of diameters <3.0 mm in 2nd-generation 320-slice CT. XIENCE Phantom Study part 2. *Int J Cardiol.* 2016; 202: 541-545. doi: [10.1016/j.ijcard.2015.09.038](https://doi.org/10.1016/j.ijcard.2015.09.038)
6. Zhang LJ, Wu SY, Wang J, et al. Diagnostic accuracy of dual-source CT coronary angiography: The effect of average heart rate, heart rate variability, and calcium score in a clinical perspective. *Acta Radiol.* 2010; 51: 727-740. doi: [10.3109/02841851.2010.492792](https://doi.org/10.3109/02841851.2010.492792)
7. Tomizawa N, Maeda E, Akahane M, Torigoe R, Kiryu S, Ohtomo K. Coronary CT angiography using the second-generation 320-detector row CT: Assessment of image quality and radiation dose in various heart rates compared with the first-generation scanner. *Int J Cardiovasc Imaging.* 2013; 29: 1613-1618. doi: [10.1007/s10554-013-0238-2](https://doi.org/10.1007/s10554-013-0238-2)

8. Wong DT, Soh SY, Ko BS, et al. Superior CT coronary angiography image quality at lower radiation exposure with second generation 320-detector row CT in patients with elevated heart rate: A comparison with first generation 320-detector row CT. *Cardiovasc Diagn Ther*. 2014; 4: 299-306. doi: [10.3978/j.issn.2223-3652.2014.08.05](https://doi.org/10.3978/j.issn.2223-3652.2014.08.05)
9. Latif MA, Sanchez FW, Sayegh K, et al. Volumetric single-beat coronary computed tomography angiography: Relationship of image quality, heart rate, and body mass index. Initial patient experience with a new computed tomography scanner. *J Comput Assist Tomogr*. 2016. doi: [10.1097/RCT.0000000000000428](https://doi.org/10.1097/RCT.0000000000000428)
10. Ghekiere O, Nchimi A, Djekic J, et al. Coronary computed tomography angiography: patient-related factors determining image quality using a second-generation 320-slice CT scanner. *Int J Cardiol*. 2016; 221: 970-976. doi: [10.1016/j.ijcard.2016.07.141](https://doi.org/10.1016/j.ijcard.2016.07.141)
11. Meng L, Cui L, Cheng Y, et al. Effect of heart rate and coronary calcification on the diagnostic accuracy of the dual-source CT coronary angiography in patients with suspected coronary artery disease. *Korean J Radiol*. 2009; 10: 347-354. doi: [10.3348/kjr.2009.10.4.347](https://doi.org/10.3348/kjr.2009.10.4.347)
12. Park MJ, Jung JI, Choi YS, et al. Coronary CT angiography in patients with high calcium score: Evaluation of plaque characteristics and diagnostic accuracy. *Int J Cardiovasc Imaging*. 2011; 27: 43-51. doi: [10.1007/s10554-011-9970-7](https://doi.org/10.1007/s10554-011-9970-7)
13. Vavere AL, Arbab-Zadeh A, Rochitte CE, et al. Coronary artery stenoses: Accuracy of 64-detector row CT angiography in segments with mild, moderate, or severe calcification—a subanalysis of the CORE-64 trial. *Radiology*. 2011; 261: 100-108. doi: [10.1148/radiol.11110537](https://doi.org/10.1148/radiol.11110537)
14. Chen CC, Chen CC, Hsieh IC, et al. The effect of calcium score on the diagnostic accuracy of coronary computed tomography angiography. *Int J Cardiovasc Imaging*. 2011; 37-42. doi: [10.1007/s10554-011-9955-6](https://doi.org/10.1007/s10554-011-9955-6)
15. Palumbo A, Maffei E, Martini C, et al. Coronary calcium score as gatekeeper for 64-slice computed tomography coronary angiography in patients with chest pain: per-segment and per-patient analysis. *Eur Radiol*. 2009; 19: 2127-2135. doi: [10.1007/s00330-009-1398-2](https://doi.org/10.1007/s00330-009-1398-2)
16. Tanaka R, Yoshioka K, Muranaka K, et al. Improved evaluation of calcified segments on coronary CT angiography: A feasibility study of coronary calcium subtraction. *Int J Cardiovasc Imaging*. 2013; 29: 75-81. doi: [10.1007/s10554-013-0316-5](https://doi.org/10.1007/s10554-013-0316-5)
17. Sun Z, Ng C. High calcium scores in coronary CT angiography: Effects of image post-processing on visualization and measurement of coronary lumen diameter. *J Med Imaging Health Inf*. 2015; 5: 110-116. doi: [10.1166/jmih.2015.1366](https://doi.org/10.1166/jmih.2015.1366)
18. Sun Z, Ng KC, Xu L, Fan Z, Lei J. Coronary CT angiography in heavily calcified coronary arteries: Improvement of coronary lumen visualization and coronary stenosis assessment with image post-processing methods. *Medicine*. 2015; 94: e2148. doi: [10.1097/MD.0000000000002148](https://doi.org/10.1097/MD.0000000000002148)
19. Sun Z, Xu L, Fan Z. Coronary CT angiography in calcified coronary plaques: Comparison of diagnostic accuracy between bifurcation angle measurement and coronary lumen assessment for diagnosing significant coronary stenosis. *Int J Cardiol*. 2016; 203: 78-86. doi: [10.1016/j.ijcard.2015.10.079](https://doi.org/10.1016/j.ijcard.2015.10.079)
20. Xu L, Sun Z. Coronary CT angiography evaluation of calcified coronary plaques by measurement of left coronary bifurcation angle. *Int J Cardiol*. 2015; 182: 229-231. doi: [10.1016/j.ijcard.2014.12.114](https://doi.org/10.1016/j.ijcard.2014.12.114)
21. Sun Z. Coronary CT angiography in coronary artery disease: Correlation between virtual intravascular endoscopic appearances and left bifurcation angulation and coronary plaques. *Biomed Res Int*. 2013; 2013: 732059. doi: [10.1155/2013/732059](https://doi.org/10.1155/2013/732059)
22. Sun Z, Dimpudus FJ, Nugroho J, Adipranoto JD. CT virtual intravascular endoscopy assessment of coronary artery plaques: A preliminary study. *Eur J Radiol*. 2010; 75: e112-e119. doi: [10.1016/j.ejrad.2009.09.007](https://doi.org/10.1016/j.ejrad.2009.09.007)
23. Xu L, Sun Z. Virtual intravascular endoscopy visualization of calcified coronary plaques: A novel approach of identifying plaque features for more accurate assessment of coronary lumen stenosis. *Medicine*. 2015; 94(17): e805. doi: [10.1097/MD.0000000000000805](https://doi.org/10.1097/MD.0000000000000805)
24. Chaichana T, Sun Z, Jewkes J. Computation of hemodynamics in the left coronary artery with variable angulations. *J Biomech*. 2011; 44: 1869-1878. doi: [10.1016/j.jbiomech.2011.04.033](https://doi.org/10.1016/j.jbiomech.2011.04.033)
25. Markl M, Wegent F, Zech T, et al. In vivo wall shear stress distribution in the carotid artery: Effect of bifurcation geometry, internal carotid artery stenosis, and recanalization therapy. *Circ Cardiovasc Imaging*. 2010; 3: 647-655. doi: [10.1161/CIRCIMAGING.110.958504](https://doi.org/10.1161/CIRCIMAGING.110.958504)
26. Arjmandi Tash O, Razavi SE. Numerical investigation of pulsatile blood flow in a bifurcation model with a non-planar branch: The effect of different bifurcation angles and non-planar branch. *Bioimpacts*. 2012; 2: 195-205. doi: [10.5681/bi.2012.023](https://doi.org/10.5681/bi.2012.023)
27. Rodriguez-Granillo GA, Garcia-Garcia HM, Wentzel J, et al. Plaque composition and its relationship with acknowledged shear stress patterns in coronary arteries. *J Am Coll Cardiol*. 2006; 47: 884-885. doi: [10.1016/j.jacc.2005.11.027](https://doi.org/10.1016/j.jacc.2005.11.027)
28. Park JB, Choi G, Chun EJ, et al. Computational fluid dynamic measures of wall shear stress are related to coronary lesion characteristics. *Heart*. 2016. doi: [10.1136/heartjnl-2016-309299](https://doi.org/10.1136/heartjnl-2016-309299)
29. Pang CL, Alcock R, Pilkington N, Reis T, Roobottom C.

Determining the haemodynamic significance of arterial stenosis: The relationship between CT angiography, computational fluid dynamics, and non-invasive fractional flow reserve. *Clin Radiol.* 2016; 71: 750-757. doi: [10.1016/j.crad.2016.03.001](https://doi.org/10.1016/j.crad.2016.03.001)

30. Sun Z, Cao Y. Multislice CT angiography assessment of left coronary artery: Correlation between bifurcation angle, dimensions and development of coronary artery disease. *Eur J Radiol.* 2011; 79: e90-e95. doi: [10.1016/j.ejrad.2011.04.015](https://doi.org/10.1016/j.ejrad.2011.04.015)

31. Temov K, Sun Z. Coronary computed tomography angiography investigation of the association between left main coronary artery bifurcation angle and risk factors of coronary artery disease. *Int J Cardiovasc Imaging.* 2016; 32(Suppl 1): S129-S137. doi: [10.1007/s10554-016-0884-2](https://doi.org/10.1007/s10554-016-0884-2)

32. Tesche C, De Cecco CN, Caruso D, et al. Coronary CT angiography derived morphological and functional quantitative plaque markers correlated with invasive fractional flow reserve for detecting hemodynamically significant stenosis. *J Cardiovasc Comput Tomogr.* 2016; 10: 199-206. doi: [10.1016/j.jcct.2016.03.002](https://doi.org/10.1016/j.jcct.2016.03.002)